ORCA SURGICAL

A Part of CTZ Group

Clinical Review

EBK™ + CLEAR

EBK™ CLEAR – A NEW STANDARD OF CARE FOR REFRACTIVE LASER SURGERIES

Sari Prutchi Sagiv, Rachel Hersh, Yariv Bar-On. *Orca Surgical, ISRAEL*

Contents

Introduction: The Challenges in Epithelium Removal ……..1
PRK vs LASIK……2
Corneal healing……2
Preserving corneal health and integrity……3
Corneal haze and post-op complications……3
EBK™ Clear – The New Standard of Care for Epithelium Removal in Refractive Surgery……3
EBK™ Clear – The Benefits……4
Faster re-epithelialization time……4
Less pain……6
Maintains integrity of Bowman's layer and basal membrane……6
Lower incidence of corneal haze……7
Enhanced post-operative visual quality……7
Safety……8
Shorter procedure duration……8
Trends and research outlook……9
Summary and conclusions……9
References……9

Abstract: EBK-Clear sets a new standard of care for epithelium removal in refractive surgery. With EBK-Clear epithelium removal can be performed without damaging or causing trauma to corneal layers. Basal membrane and Bowman's layer remain completely intact. EBK-Clear is designed to remove only the upper epithelium layer smoothly, leaving no residual cell debris on the surface. This creates an optimal surface for a successful refractive ablation. In clinical trials, EBK-Clear showed faster post-operative re-epithelialization, reduced post-operative pain and haze and minimal patient discomfort. The following review details the role EBK-Clear plays in refractive surgery and outlines the important clinical trial results.

Introduction: Challenges in Epithelium removal

Surgery to correct refractive errors has become one of the most frequently performed and well-established ophthalmic surgeries across the world. In the US alone, 1.4 million procedures were performed in 2007 [1, 2]. Refractive correction is performed by a laser ablation of the cornea and requires a prior removal of the epithelium layer. Several methods are currently in use. In PRK (Photorefractive Keratotomy), the epithelium is scratched off with a mechanical device. In other techniques such as LASIK (laser-assisted in situ keratomileusis), straight cuts through the cornea to create a surface opening flap are performed. In the SMILE (small incision lenticule extraction) procedure, an intrastromal lenticule is created to remove the ablated material. Most surgeons agree that epithelium removal is the most critical part of the procedure. The invasive impact of these methods on the cornea differs, and as a result, strongly influences post-operative healing and clinical outcomes.

EBK™-CLEAR – A NEW STANDARD OF CARE FOR REFRACTIVE LASER SURGERIES

PRK vs LASIK

In PRK the epithelium is in general pre-treated with alcohol before it is scraped off using a metal spud, brush or other device. Although this method is effective, there are a number of disadvantages. Mechanical epithelium removal may cause trauma to the basal membrane and Bowman's layer, which critically affects corneal healing. PRK is strongly dependent on the surgical skills of the doctor in order to prevent damage to layers beneath the epithelium. Also, epithelium residuals often remain, which may influence the accuracy of ablation by the excimer laser. The primary post-operative adverse effects following PRK include pain, myopic regression or corneal haze [3]. Furthermore, the use of alcohol in PRK has toxic side effects and not only dehydrates the corneal surface but also causes pain [4-6].

Although LASIK, which creates a corneal flap, was developed to lower post-operative complications and haze, there has been significant evidence of other post-operative complications, such as disruption of the anterior stroma lamellae, which critically weakens the biomechanical properties of the cornea after surgery [7]. Undesired consequences can be severe pain and flap complications [8]. The severe nature of flap complications and their repair has recently led surgeons to reconsider PRK [9]. Dr. Marguerite McDonalds, the first surgeon to perform refractive laser surgery in the US, suggested in an interview with *Cataract & Refractive Surgery Today* on *A return to PRK*:

"I believe PRK is currently the best available means of visual correction..... Among other information, I tell patients that PRK corrects vision without an incision." [10].

Corneal Healing

Corneal healing after ablation is a complex process which starts with the removal of ablated necrotic cells and re-epithelialization to protect the lower layers of the cornea. The open area is usually covered by a new epithelium monolayer within 4 days [3]. While PRK causes a wide wound repair response due to induced damages to all upper corneal layers, including the Bowman's layer, in LASIK these layers stay unaffected, but wound healing is required on flap edges and underneath [11]. LASIK also damages the innervation of the cornea which requires longer recovery time [12]. The epithelium starts to recover from the limbus and the basal epithelial layer from which epithelial cells migrate and proliferate to close the open wound.

Current epithelium removal techniques may damage the basal membrane and Bowman's layer, strongly influencing post-operative healing and clinical outcomes

The depth of the wound inflicted by epithelium removal, trauma like scratches or the removal of the basal membrane and Bowman's layer by the procedure may prolong this process [3, 13]. A smooth ablated anterior stromal surface accelerates epithelial adhesion and migration with faster epithelial wound closure than a more irregular ablated stromal bed [14, 15]. The migrating epithelial cells find an anchoring surface on the basal membrane to connect to the underlying stroma. The basal membrane functions further in wound modulation as a barrier against migration factors which are released from the epithelium [16]. Therefore, damages to the basal membrane might aggravate the migration of epithelial cells in wound repair process.

EBK™-CLEAR – A NEW STANDARD OF CARE FOR REFRACTIVE LASER SURGERIES

Preserving corneal health and integrity

The importance of an intact Bowman's layer is not only significant for the healing process after epithelium injury but also as a general stabilizing factor of the corneal structure. Lagali *et al*. reported that even a partial intact Bowman layer significantly improves the post-operative re-innervation of the epithelium layer after laser surgery due to less damage to the crucial cell structures [13]. In general without Bowman's layer and the underlying sub-epithelial nerve plexus, the regeneration of sub-basal nerves was delayed. Therefore, Bowman's layer functions as protection to the underlying sub-epithelial nerve plexus which is essential for the rapid recovery of sub-basal nerves [13].

Corneal haze and post-op complications

An additional side effect of refractive surgery is corneal haze, which occurs due to irregular wound healing after excimer laser surgery, causing visual impairment. An intact Bowman's layer and basal membrane were found to be crucial to reduce haze after eye surgery [16-18].

Finally, the risk of post-op bacterial infections increases with extended wound healing and wound closure duration. At the same time inflammatory processes are prolonged. Infection is a primary risk of epithelium removal techniques such as PRK [19, 20]. Faster re-epithelialization and wound closure may reduce the risk of infection and inflammation.

There is a clear unmet clinical need for a safer, faster, more delicate and more efficient epithelium removal procedure that preserves and maintains Bowman's layer and basal membranes intact to ensure a healthy cornea and to speed up recovery.

EBK™-Clear – The New Standard of Care for Epithelium Removal in Refractive Surgery

EBK-Clear is the first procedure that non-traumatically ablates the upper epithelium layer without damaging the basal membrane and Bowman's layer (Figure 1A). Epithelium removal via EBK-Clear leaves smooth edges and has minimal impact on the cornea surface compared to PRK (Figure 1B) [21].

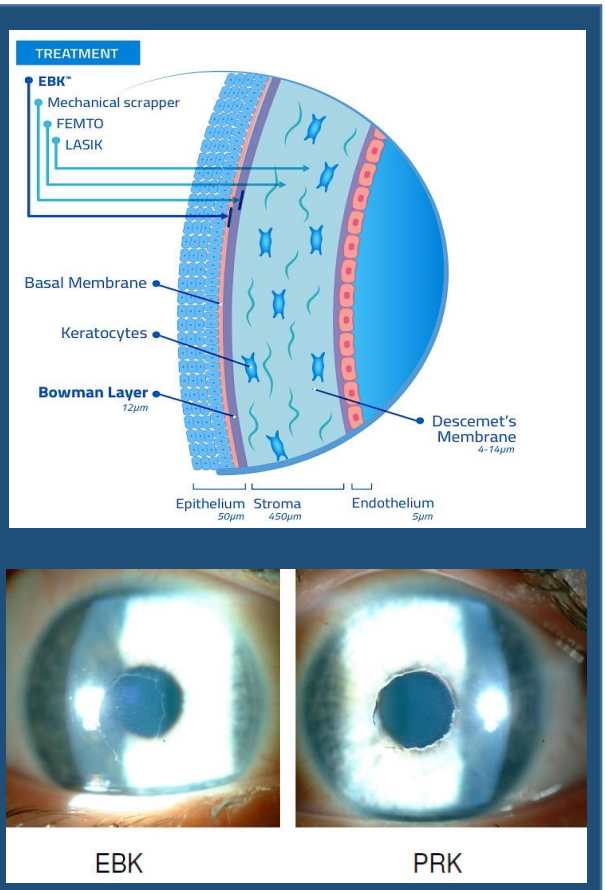

Figure 1: A) Comparison of several epithelial removal techniques to EBK-Clear. Basal membrane and Bowman's layer are maintained intact only with the EBK-Clear method. B) Treatment of the same patient with EBK-Clear in one eye and PRK in the other eye. EBK-Clear treatment shows smooth edges and minimal impact on cornea surface compared to PRK [24].

EBK™-CLEAR – A NEW STANDARD OF CARE FOR REFRACTIVE LASER SURGERIES

The EBK-Clear procedure is performed by using Epi-Clear, a CE-Mark and FDA approved single use, sterile, fully disposable handle with a multi-blade tip (Figure 2). The special curve on the handle allows convenient loading and extraction of the tip. The bowl-shaped polymer double blades gently sweep away the epithelium and simultaneously collect discarded epithelial cells in the receptacle for safe and complete removal to create the optimal laser treatment bed.

Figure 2: Epi-Clear device - Single use, sterile, fully disposable handle with multi-blade tip

EBK-Clear – The Benefits

EBK-Clear procedure has been part of over 10 independent clinical trials with over 500 eyes over the last four years to evaluate its safety and efficacy of this as a novel method in refractive surgery compared to standard mechanical epithelium removal methods [23-27]. The clinical results demonstrate that EBK-Clear minimizes corneal trauma during epithelium removal, preserving and maintaining the basal membrane and Bowman's layer intact. Post-operative wound healing and re-epithelialization are significantly faster and patients' self-reported post-operative pain levels are lower than those reported using standard techniques, such as mechanical removal or alcohol-assisted debridement. In addition, EBK-Clear is a fast procedure (mean procedure time: 8-10 seconds) and technically easy to perform with highly reliable and reproducible results.

Patient discomfort caused by the epithelium removal is minimal. The epithelium is swept away and collected layer by layer and the stroma is never scratched. Table 1 displays highlights of selected prospective, contra-lateral performed clinical trials comparing EBK-Clear to standard mechanical PRK methods.

Faster re-epithelialization time

One of the most important findings of the studies performed is a significantly faster re-epithelialization with EBK-Clear compared to conventional methods used for mechanical epithelium removal [21, 23, 24, 25, 27, 28].

Nagy *et al.* investigated the process of epithelium closure and evaluated the epithelium free area centrally with anterior segment OCT. The epithelium free area re-epithelialized significantly faster following the EBK-Clear procedure compared to PRK at 1 and 2 days post-operative [28] (Figure 3). The duration of complete epithelium closure was investigated in a study performed by Shetty *et al*. In 30 eyes, a complete closure of EBK-Clear treated corneas within 3.16 ± 0.77 days was observed, while epithelium closure using a conventional mechanical spud occurred only after 3.73 ± 0.54 days ($p<0.01$) [25]. Additionally, Matsliah *et al.* showed complete re-epithelialization within 48 hours in 96% of the patients tested (n=80) [26]. Finally, Guell *et al*. reported a 97% closure within 20 hours post-operative in patients treated with EBK-Clear compared to treatment with a mechanical scraper [23].

Clinical results demonstrate that EBK-Clear minimizes corneal trauma during epithelium removal, preserving and maintaining the basal membrane and Bowman's layer intact.

EBK™-CLEAR – A NEW STANDARD OF CARE FOR REFRACTIVE LASER SURGERIES

Ref.	Principal Investigator	# of eyes	Adverse events	Results and conclusions as compared to PRK
[25]	Prof. Rohit Shetty, Narayana Nethralaya Eye Hospital, Bangalore, India	60	Not reported	Significant reduced surgery time and pain, improved re-epithelialization in quantity and quality and intact Bowman's layer integrity
[23]	Prof. Jose Luis Guell, Instituto de Microcirugia Ocular de Barcelona, Spain	50	Not reported	Faster re-epithelialization, less haze and a quicker recovery of vision. Straightforward to use with a short learning curve
[24]	Prof. Bartlomiej J. Kaluzny, Collegium Medicum, Nicolaus Copernicus University, Bydgoszcz, Poland	60	Not reported	Mean time of the surgery was 30% shorter, easy epithelium removal, increased patient comfort during the surgery and faster re-epithelialization time
[28]	Prof. Zoltan Z. Nagy, Semmelweis University Budapest	12	Not reported	Significant reduced pain, faster re-epithelialization
[26]	Dr. Matsliah Taieb, private clinic, Jerusalem, Israel	160	2 cases of transitory grade 1 haze	Quick procedure, technically easy to perform, maintains stroma integrity, moderate pain and short healing (96% of patients healed within 48 h), no case of under correction.
[27]	Dr. Matsliah Taieb, private clinic, Jerusalem, Israel	200	Not reported	Significantly faster re-epithelialization. Significant less post-operative pain
[21]	Prof. Zoltan Z. Nagy, Semmelweis University Budapest	20	Not reported	Re-epithelialization significantly quicker. Less pain

Table 1: Selected clinical studies of EBK™- Clear investigating efficacy and safety of the product and long term effects.

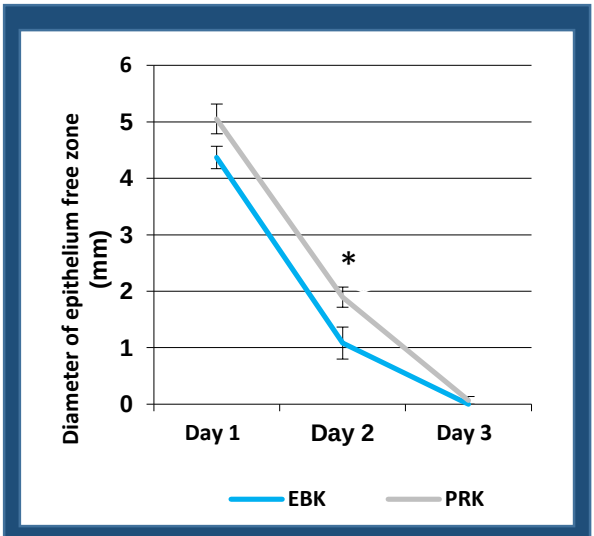

*Figure 3: Re-epithelialization process is faster on days 1 and 2 post-operative with EBK-Clear as compared to PRK procedure. Statistically significant differences displayed as *p = 0.04 [28].*

Furthermore, the re-epithelialization process with EBK-Clear is smoother and more regular. Shetty *et al*. demonstrated via Optovue in EBK-Clear treated patients (Figure 4A) a smoother re-epithelialization process resulting in a more even surface one week post-operative compared to patients treated with a conventional mechanical scraper (Figure 4B) [25]. Kaluzny *et al*. further supported these results [24].

EBK™-CLEAR – A NEW STANDARD OF CARE FOR REFRACTIVE LASER SURGERIES

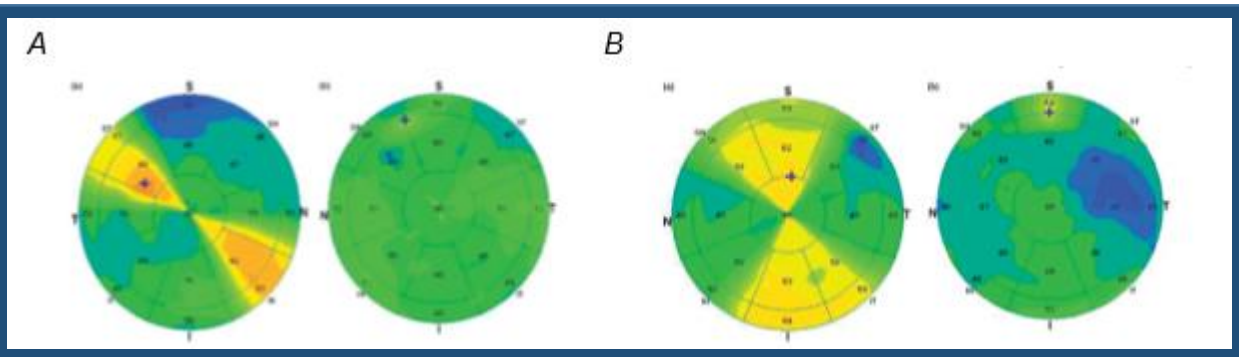

Figure 4: Re-epithelialization process of cornea. Optovue showed regular and smooth corneal healing in patients in the EBK-Clear subgroups (A) compared with the mechanical scraper subgroup (B), which showed irregular healing with epithelial edema lasting up to 1 week and epithelial thinning in few quadrants [25].

Less pain

Post-operative pain caused by removal of the epithelium is the most common discomfort described by patients undergoing refractive surgery. Pain is mostly caused by disruption of the cornea, which is densely innervated by nerve fibers of the ophthalmic division of the trigeminal nerve. Radially oriented thick stromal nerve bundles penetrate the limbus in the anterior and middle third of the stroma. The sub-basal nerve plexus is formed by stromal nerve bundles parallel to and between the basal membrane and Bowman's layer [29, 30]. In PRK the sub-basal nerve plexus and the anterior stroma is usually destroyed. The remaining nerve trunks cause post-operative pain.

Several studies demonstrate lower post-op pain level reported by EBK-Clear treated patients. By using the VAS pain scale, Nagy *et al.* showed lower levels of pain in EBK-Clear treated patients on days 1, 2 and 3 post-operative as compared to PRK [21]. Shetty *et al.* investigated the post-operative pain level using the Wong-Baker scale and revealed significant reduced pain immediately post-operative and 3 days post-op compared to a mechanical scrapper (Figure 5) [25]. Matsliah *et al.* showed reduced levels of pain when comparing EBK-Clear to conventional mechanical epithelium removal in 200 eyes [27].

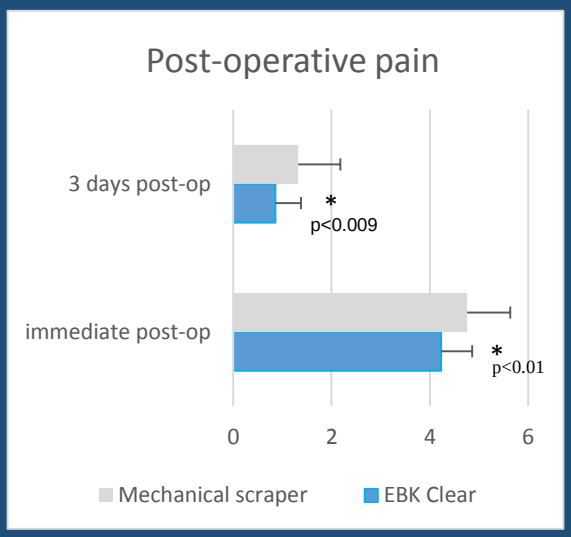

Figure 5: Pain scores in patients following EBK-Clear and PRK treatment. Using Wong-Baker scale of 1-10 with 10 being the most painful, reduced pain was measured in patients treated with EBK-Clear versus PRK, [25]

Maintains integrity of Bowman's layer and basal membrane

Damage and trauma to Bowman's layer and the basal membrane during removal of the epithelium in the current gold standard methods, such as alcohol-assisted and metal spud removal, are reported to be one of the main influences on reduced healing processes [4]. Shetty *et al.* demonstrate that EBK-Clear maintains Bowman's layer and the basal membrane completely intact and provides a smooth surface optimal for re-epithelialization (Figure 6) [25].

EBK™-CLEAR – A NEW STANDARD OF CARE FOR REFRACTIVE LASER SURGERIES

They illustrated, by intra-operative spectral domain optical coherence tomography, the effect of EBK-Clear on corneal surfaces as compared to conventional alcohol-based metal spud device removal (Figure 6). They discovered that use of EBK-Clear resulted in a smooth epithelium free surface (Figure 6A) while the alcohol assisted metal spud method created "nicks" an irregularities on the corneal surface (Figure 6B) [25].

Lower incidence of corneal haze

Development of haze is associated with damage to the corneal surface and Bowman's layer [31]. Abnormal post-operative haze after refractive surgery was shown to be treatable by a Bowman's layer transplantation, underscoring its importance [18]. When corneal haze was measure in the EBK-Clear studies, Guell *et al*. reports less haze post-op in 25 eyes [23]. Nagy did not show a difference in haze in EBK VS PRK treatment.

Enhanced post-operative visual quality

Shetty et al. evaluated the effect of EBK-Clear and PRK on post-operative visual quality. Patients treated with EBK-Clear exhibited higher focus post-operative measured by MTF compared to PRK (Figure 7 A).

Evaluation with OQAS revealed less blurred vision (Figure 7B) in patients treated with EBK-Clear for epithelium removal [25].

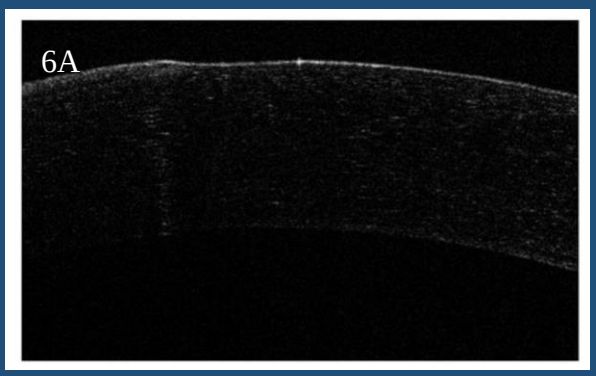

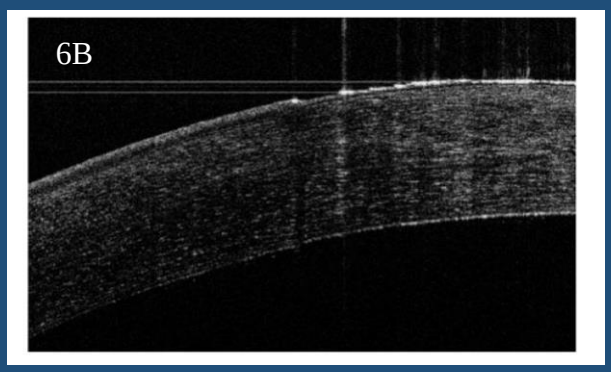

Figure 6: Intra-operative spectral domain optical coherence tomography (SD OCT) image following epithelial removal with (A) Epi-Bowman keratectomy showing an intact and smooth Bowman's layer and (B) mechanical scraper showing minute "nicks" and irregularities in the Bowman's layer [25]

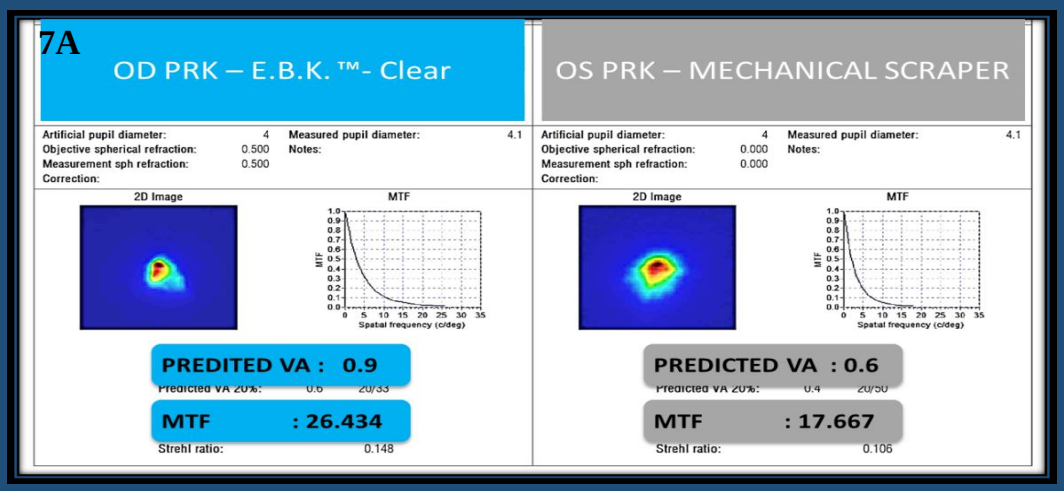

EBK™-CLEAR – A NEW STANDARD OF CARE FOR REFRACTIVE LASER SURGERIES

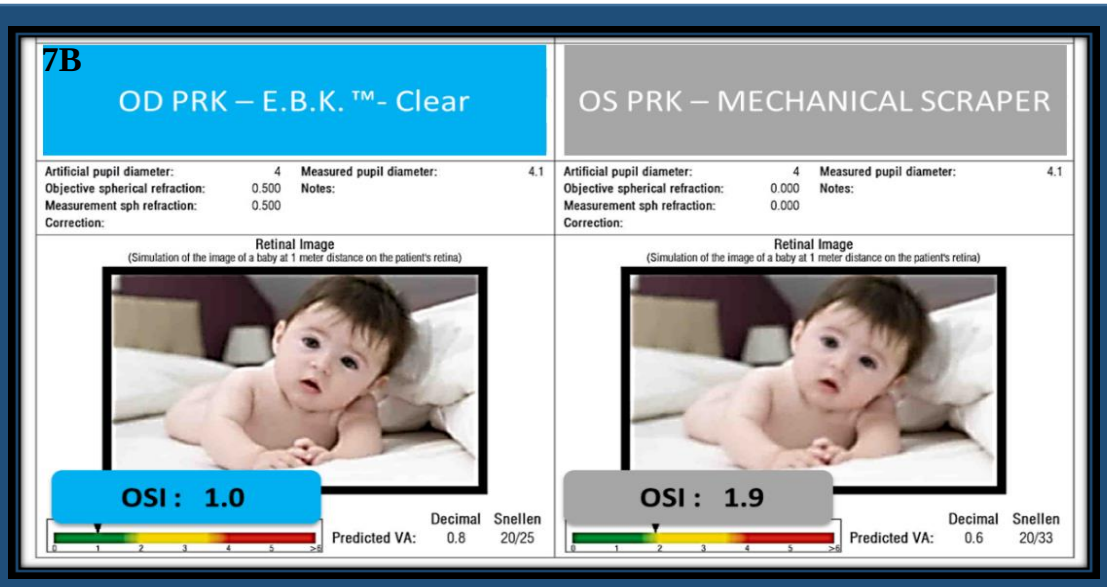

Figure 7: Post-operative visual quality in patients treated with either EBK-Clear or PRK. A) Analysis of MTF revealed a better post-operative focus in patients treated with EBK-Clear compared to PRK. B) Less blurred vision detected in EBK-Clear patients measured by OQAS [25].

Safety

EBK-Clear offers surgeons a safe and reliable method to remove the epithelium layer that minimizes damage or trauma to the sub-epithelium corneal layers, such as Bowman's layer or stroma.

No adverse effects or trauma to the cornea have been reported in the 10 EBK-Clear clinical trials encompassing more than 500 eyes. There were no complications noticed intraoperatively or any complications, disturbances in epithelial healing or inflammation reported during the 30-day follow-up period.

Furthermore, this procedure has been performed commercially in Europe and Asia on over 6,000 patients. No safety issues have been raised or associated with EBK-Clear or in the follow-up periods of up to 3 years.

The fact that no sterilization is required is another safety advantage of EBK-Clear compared to PRK. This helps avoid trans-infections and reduces the general risk of infection. The EPI-Clear device is fully disposable, for single use only.

Shorter procedure duration

The time required for epithelium removal is an important factor in procedures such as PRK. Prolonged exposure of the stroma to air can cause stromal dehydration and thinning which can have detrimental effects on surgical outcomes. EBK-Clear minimizes the time needed to completely remove the epithelium and clean the corneal surface of epithelium cell residue. This may be due to the cell collecting tip of the EPI-Clear device which removes the ablated epithelium cells, eliminating the needs for further cleaning and mechanical epithelial cell removal.

Matsliah *et al.* reports that the average time needed for epithelium removal is approximately 8-10 seconds per eye to obtain a clean surface [26]. Shetty measured a significant reduction in procedure time with EBK-Clear compared to the mechanical scraper (16.44 ± 6.23s *vs* 38.12 ± 8.32s ($p<0.0001$) respectively) [25].

EBK™-CLEAR – A NEW STANDARD OF CARE FOR REFRACTIVE LASER SURGERIES

Trends and research outlook

The role of the basal membrane and the Bowman's layer to the healing process after epithelium injury will be closely investigated in a worldwide multicenter clinical trial. EBK-Clear will be investigated further for its potential benefits in the inflammatory reaction after refractive surgery which is connected to long term post-operative complications, such as cornea ectasia and cornea erosions. The connection between injured corneal innervation to dry eye syndrome and the re-innervation of the injured eye is another focus of this multicenter trial.

Summary and conclusions

EBK-Clear has the potential to revolutionize the laser assisted refractive surgery market. It provides a delicate, minimal and non-invasive treatment platform that induces no damage to the corneal surface, potentially reducing the risk of long term post-operational complications. The importance to maintain crucial structures for target refraction and post-operative healing processes has been shown in a multitude of previous work and will be further investigated in ongoing clinical trials.

The EBK-Clear procedure is the only technique to remove the epithelium that preserves Bowman's layer, removing the epithelium layer by layer to create clear and graduated borders for enhanced healing.

.

EBK-Clear has the potential to reduce side effects and complications. It is suitable for patients with thin corneas and completely preserves the biomechanical integrity of the cornea.

By creating a smoother and superior treatment bed free of epithelial cell residue, EBK-Clear allows more precise refractive correction, reduces post-op pain and facilitates faster recovery.

Orca Surgical, a part of CTZ group, was founded in 2011. Orca develops pioneering solutions for ophthalmologic surgery focused on the cornea based on its novel EBK™ (Epi-Bowman's Keratectomy) technology.

Authors contact:

Yariv Bar-On - yariv@orcasurgical.com
Sari Prutchi-Sagiv PhD – sari@ctz.co.il
Rachel Hersh - rachel@orcasurgical.com

References

1. Corcoran KJ: **Macroeconomic landscape of refractive surgery in the United States.** *Curr Opin Ophthalmol* 2015, **26:**249-254.
2. Erie JC: **Corneal wound healing after photorefractive keratectomy: a 3-year confocal microscopy study.** *Trans Am Ophthalmol Soc* 2003, **101:**293-333.
3. Tomas-Juan J, Murueta-Goyena Larranaga A, Hanneken L: **Corneal Regeneration After Photorefractive Keratectomy: A Review.** *J Optom* 2015, **8:**149-169.
4. Abad JC, Talamo JH, Vidaurri-Leal J, Cantu-Charles C, Helena MC: **Dilute ethanol versus mechanical debridement before photorefractive keratectomy.** *J Cataract Refract Surg* 1996, **22:**1427-1433.
5. Campos M, Szerenyi K, Lee M, McDonnell JM, Lopez PF, McDonnell PJ: **Keratocyte loss after corneal deepithelialization in primates and rabbits.** *Arch Ophthalmol* 1994, **112:**254-260.
6. Helena MC, Filatov VV, Johnston WT, Vidaurri-Leal J, Wilson SE, Talamo JH: **Effects of 50% ethanol and mechanical epithelial debridement on corneal structure before and after excimer photorefractive keratectomy.** *Cornea* 1997, **16:**571-579.
7. Ang EK, Couper T, Dirani M, Vajpayee RB, Baird PN: **Outcomes of laser refractive surgery for myopia.** *J Cataract Refract Surg* 2009, **35:**921-933.

EBK™-CLEAR – A NEW STANDARD OF CARE FOR REFRACTIVE LASER SURGERIES

8. Murray A, Jones, L., Milne, A., Fraser, C., Lourenco, T., Burr, J.: **A systematic review of the safety and efficacy of elective photorefractive surgery for the correction of refractive error : Interventional Procedures Programme, National Institute for Health and Clinical Excellence : review body report.** *[London] : National Institute for Clinical Excellence, [2005]* 2005**:**xxiii, 149 leaves : ill.
9. B. B: **PRK: Feeling Better and Healing Faster.** *EyeNet Magazine* 2008.
10. M. M: **A Return to PRK - Why I currently favor advanced surface ablation and how I market the procedure.** *Cataract & Refractive Surgery Today* 2007, **May**.
11. Dupps WJ, Jr., Wilson SE: **Biomechanics and wound healing in the cornea.** *Exp Eye Res* 2006, **83:**709-720.
12. Chao C, Golebiowski B, Stapleton F: **The role of corneal innervation in LASIK-induced neuropathic dry eye.** *Ocul Surf* 2014, **12:**32-45.
13. Lagali N, Germundsson J, Fagerholm P: **The role of Bowman's layer in corneal regeneration after phototherapeutic keratectomy: a prospective study using in vivo confocal microscopy.** *Invest Ophthalmol Vis Sci* 2009, **50:**4192-4198.
14. Lombardo M, Serrao S: **Smoothing of the ablated porcine anterior corneal surface using the Technolas Keracor 217C and Nidek EC-5000 excimer lasers.** *J Refract Surg* 2004, **20:**450-453
15. Steele JG, Johnson G, McLean KM, Beumer GJ, Griesser HJ: **Effect of porosity and surface hydrophilicity on migration of epithelial tissue over synthetic polymer.** J *Biomed Mater Res 2000*, 50:475-482
16. Torricelli AA, Singh V, Santhiago MR, Wilson SE: **The corneal epithelial basement membrane: structure, function, and disease.** *Invest Ophthalmol Vis Sci* 2013, **54:**6390-6400.
17. Chuo JY, Yeung SN, Rocha G: **Modern corneal and refractive procedures.** *Expert Rev Ophthalmol* 2011, **6:**247–266.
18. Lie J, Droutsas K, Ham L, Dapena I, Ververs B, Otten H, van der Wees J, Melles GR: **Isolated Bowman layer transplantation to manage persistent subepithelial haze after excimer laser surface ablation.** *J Cataract Refract Surg* 2010, **36:**1036-1041.
19. Karp CL, Tuli SS, Yoo SH, Vroman DT, Alfonso EC, Huang AH, Pflugfelder SC, Culbertson WW: **Infectious keratitis after LASIK.** *Ophthalmology* 2003, **110:**503-510.
20. Solomon R, Donnenfeld ED, Holland EJ, Yoo SH, Daya S, Guell JL, Mah FS, Scoper SV, Kim T: **Microbial keratitis trends following refractive surgery: results of the ASCRS infectious keratitis survey and comparisons with prior ASCRS surveys of infectious keratitis following keratorefractive procedures.** *J Cataract Refract Surg* 2011, **37:**1343-1350
21. Nagy Z.Z. GA, Szekrényesi C., Filkorn T., Kránitz K., Juhász É., Tóth G., Kovács l.: **Epi-Bowman Keratectomy: A new technique for the improvement of outcomes in surface ablation procedures.** *ESCRS AMSTERDAM* 2013.
22. Nagy ZZ: **PPK after EBK or standard removal. Contralateral eye study.**
23. J. G: **The use of a novel device for removal of the epithelium in surface ablation procedures.** *ESCRS, Warsaw* 2013.
24. Kaluzny BJ, Szkulmowski M., Grulkowski I., Wojtkowski M.: **Epi-Bowman Keratectomy vs. alcohol-assisted PRK: healing process evaluation with Spectral OCT with novel speckle reduction technique.** *ESCRS, Amsterdam* 2013.
25. Shetty R, Nagaraja H, Pahuja NK, Jayaram T, Vohra V, Jayadev C: **Safety and Efficacy of Epi-Bowman Keratectomy in Photorefractive Keratectomy and Corneal Collagen Cross-Linking: A Pilot Study.** *Curr Eye Res* 2015**:**1-7.
26. Taieb M: **E.B.K [Epi-Bowman Keratectomy]. Long term results[160 eyes].** *Poster presented at ESCRS, Amsterdam* 2013.
27. Taieb M: **Epi-Bowman Keratectomy with new device for surface 6 months follow up.** 2013.
28. Nagy Z.Z. GA, Szekrényesi C., Filkorn T., Kránitz K., Juhász É., Tóth G., Kovács l.: **A new technique for improvement of outcomes in surface ablation procedures.** *Poster at ESCRS, Warschau* 2013.
29. B S: **Nerve structures in human central corneal epithelium.** *Graefes Arch Clin Exp Ophthalmol 1982* 1982, **;218:**14-20.
30. Muller LJ VG, Pels L,: **Architecture of human corneal nerves.** *Invest Ophthalmol Vis Sci* 1997, **38:**985-994.
31. Wilson SL, El Haj AJ, Yang Y: **Control of scar tissue formation in the cornea: strategies in clinical and corneal tissue engineering.** *J Funct Biomater* 2012, **3:**642-687

EBK™ CROSS

EBK™ CROSS - A NEW TECHNIQUE FOR EPITHELIUM-OFF CORNEAL CROSSLINKING

Sari Prutchi Sagiv, Rachel Hersh, Yariv Bar-On – *Orca Surgical, ISRAEL*

Contents

Introduction……1
Epithelium Off vs Trans-Epithelial Crosslinking……2
Risks and disadvantages associated with current epithelium removal techniques……2
Corneal Trauma……2
Post-op pain……2
Post-op infection……2
EBK™ Cross – The New Standard of Care for Epithelium Removal in Corneal Crosslinking……3
Fast and optimized re-epithelialization ……3
Preserving the *integrity of Bowman's layer*……3
Reduced incidence of corneal haze……4
Minimal procedure time……5
Less adverse effects……5
Trends and research outlook……5
Summary and conclusions……5
References……6

Abstract:
EBK-Cross sets a new standard of care for epithelium removal in crosslinking. With EBK-Cross epithelium removal can be performed without damaging or causing trauma to corneal layers. Basal membrane and Bowman's layer remain completely intact. EBK-Cross is designed to remove only the upper epithelium layer smoothly, leaving no residual cell debris on the surface. This creates an optimal surface for a successful crosslinking procedure. In clinical trials, EBK-Cross showed faster post-operative re-epithelialization, reduced post-operative pain and haze and minimal patient discomfort. The following review details the role EBK-Cross plays in crosslinking and outlines the important clinical trial results.

Introduction

Crosslinking is becoming the gold standard procedure for treating a wide range of conditions, such as Keratoconus (KC), cornea ectasia after refractive surgery, pellucid marginal corneal degeneration (PMD) and keratitis related diseases [1-3]. Based on the Dresden protocol of 2003 [4] crosslinking is induced by the application of riboflavin solution directly on the stromal layer of the cornea stimulated by UV light (370 nm). The crosslink reaction increases the number of links between collagen fibrils in the stromal layer and strengthens the shape of the cornea [3, 5]. Long term stability of the new induced crosslink and the reshaping of the cornea have been evaluated in follow-up of up to 10 years and have shown promising results. Crosslink efficiently arrests disease progression in KC patients and improves visual quality [5-7].

EBK™-CROSS - A NEW TECHNIQUE FOR EPITHELIUM-OFF CORNEAL CROSSLINKING

Epithelium-Off vs Trans-Epithelial Crosslinking

Preparation for the procedure involves removing the epithelial layer of the cornea. This is important in order to provide sufficient absorption of the riboflavin and optimal UV penetration to induce the desired cross-link reaction [8]. Attempts to perform trans-epithelial crosslinking have not proven satisfactory to date as the corneal epithelium represents a barrier for the riboflavin molecules [8-11].

Complete removal of epithelium from the corneal stroma, as well as the smooth and even removal of this layer without traumatizing additional corneal layers such as basal membrane and Bowman's layer, were reported as key to achieve an optimal crosslink results compared to trans-epithelial procedure. In addition, remaining epithelium cell residues slows down riboflavin diffusion and penetration and might result in incomplete absorption [2, 10, 12]

Risks and disadvantages associated with current epithelium removal techniques

Corneal trauma

Mechanical methods to remove the epithelium, such as metal spud or sponge, following alcohol application is the current gold standard [13]. This method requires a very skilled hand since the quality of corneal healing and successful crosslink is not only dependent on the actual crosslink procedure, but equally on the level of trauma to the cornea from the removal of the epithelium [2, 8]. Corneal damage and scarring increase the risk of recurrent corneal erosion and haze, as well as extended pain duration and healing time. In addition corneal irregularities were shown to cause insufficient riboflavin absorption for the crosslink procedure [14, 15].

Post-op pain

Post-operative pain is mainly attributed to the removal of the epithelium layer caused by disruption of the cornea dense innervation. Stromal nerve bundles radially oriented penetrate in the anterior and middle third of the stroma. The sub-basal nerve plexus is formed by stromal nerve bundles parallel to and between the basal membrane and Bowman's layer. The nerve bundles branch out from the basal membrane layer into the epithelium [16, 17].

Post-op infection

Post-operative infections can occur although the UV-light used during the procedure has an antiseptic effect. De-epithelialization increases the risk of infection and leads to wound related inflammation [1]. Fast re-epithelialization reduces the risk of new infections during the healing process.

There is the need for a new method to effectively ablate the epithelium in a controlled and safe manner without damaging additional corneal layers, such as Bowman's layer. The smooth removal of <u>only</u> the epithelium layer is key to ensure an optimal crosslink reaction and additionally to preserve important post-procedure structures for optimal re-epithelialization.

EBK™ Cross – The new standard of care for Epithelium Removal in Corneal Crosslinking

EBK-Cross is a novel epithelium removal technique to delicately and precisely remove the epithelium in preparation for corneal crosslink procedures and while leaving Bowman's layer intact.

The EBK-Cross procedure is performed by using EPI-Clear, a CE mark and FDA approved single use, sterile fully disposable handle with a multi-blade tip (Figure 1).

EBK™-CROSS - A NEW TECHNIQUE FOR EPITHELIUM-OFF CORNEAL CROSSLINKING

The bowl-shaped polymer double blades gently sweep away the epithelium and simultaneously collect discarded epithelial cells in the receptacle for safe and complete removal to create the optimal treatment bed.

Figure 2: Epi-Clear device - Single use, sterile, fully disposable handle with multi-blade tip

Orca Surgical has performed investigator initiated clinical studies in over 60 eyes and has demonstrated that EBK-Cross significantly reduces healing time to final epithelium closure, reduces haze, pain duration and intensity, as well as reduces adverse effects and complications compared to mechanical scraping [18-20] (Figure 2-6). EBK-Cross creates an optimal riboflavin penetration surface for the crosslink procedure.

Fast and optimized re-epithelialization Following epithelium removal using EBK-Cross a more rapid re-epithelialization was observed compared to a mechanical scraper. Shetty *et al.* demonstrated that epithelium closure appeared in patients treated with EBK-Cross significantly faster than in patients treated with a mechanical spud (2.61 ± 0.31 days versus 4.17 ± 1.66 days post-operative respectively; $p<0.001$) [19]. This was further supported by Frucht *et al.* showing that 24h post-operative, one third of the epithelium was closed in all patients treated with the EK-Cross. Furthermore, in more than 90% of the patients full re-epithelialization was achieved within 3 days post-operative [18]. Kanellopoulos reported recently a total closure of epithelium within 3 days post-op if treated with EBK compared to alcohol assisted debridement (Figure 2) [20].

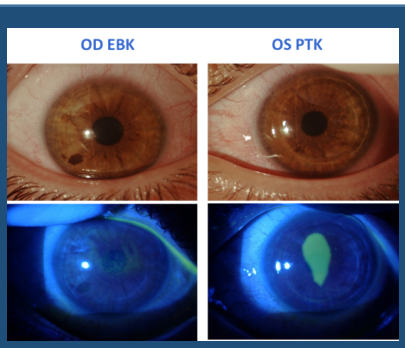

Figure 2. Duration of fully re-epithelialization. EBK-Cross treated patients showed obvious faster re-epithelialization compared to alcohol assisted epi-debridement 3 days post-op, fluorescein stained [20].

In addition, the quality of the epithelium healing process in EBK-Cross treated patients was regular and even, while the corneal surface of patients treated with the mechanical scraper showed edema and irregular surface healing [19] (Figure 3). The clean edges with the surrounding epithelium fully adherent and absence of trauma sped up re-epithelialization to make healing faster and less painful.

Preserving the integrity of Bowman's layer

Surface trauma, which can be caused by mechanical techniques to remove the epithelium, can contribute to an insufficient crosslink reaction [2]. This trauma can irreparably affect Bowman's layer. The benefits of an intact Bowman layer were revealed by van Dijk K in extreme thin corneas where crosslink reaction could not be performed due to a cornea thickness below 400 um. This procedure stabilized the fragile cornea structure revealing this important function of the Bowman's layer in KC patients [22].

Shetty *et al*. demonstrated in their clinical study that EBK-Cross preserves the integrity of the Bowman layer during epithelium removal while the mechanical scraper creates "nicks" and irregularities to Bowman's layer (Figure 4) [19]. This was further supported by a study by Frucht et al. in 17 eyes; no clinical signs of Bowman's membrane damage were demonstrated [18]

EBK™-CROSS - A NEW TECHNIQUE FOR EPITHELIUM-OFF CORNEAL CROSSLINKING

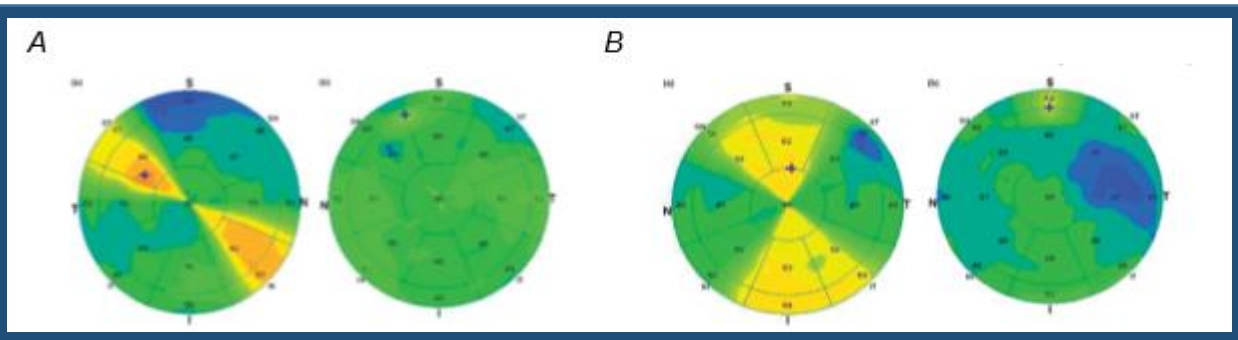

Figure 3: Re-epithelialization process of cornea. Optovue showed regular and smooth corneal healing in patients in the EBK-Cross subgroups (A) compared with the mechanical scraper subgroup (B), which showed irregular healing with epithelial edema lasting up to 1 week and epithelial thinning in few quadrants [19].

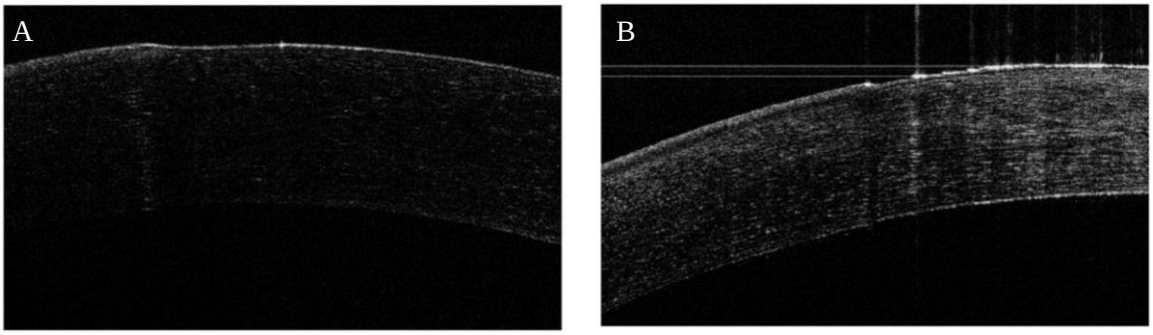

Figure 4: Intra-operative spectral domain optical coherence tomography (SD OCT) image following epithelial removal with (A) Epi-Bowman keratectomy showing an intact and smooth Bowman's layer and (B) mechanical scraper showing minute "nicks" and irregularities in the Bowman's layer [19]

Reduced incidence of corneal haze

Post-op haze occurs in up to 9% of all crosslink-treated patients after one year follow up [1, 6]. The development of haze is treatment-related and starts one month post-op. In most of patients vision is clarified 6 months post-op. Risk factors to develop haze include age, stage of disease (due to corneal thinness) and pre-operative stromal microstriae and scarring caused by damage to the cornea during epithelium removal [1, 23].

Haze development was shown to be significantly reduced in patients treated with EBK-Cross compared to mechanical removal of the epithelium. Shetty *at el.* demonstrated the reduced opacity by Scheimpflug images in patients treated with EBK-Cross (Figure 5) [19]. Opacity measurements images were shown to correlate well with subjective slit-lamp observations analyzing haze [24].

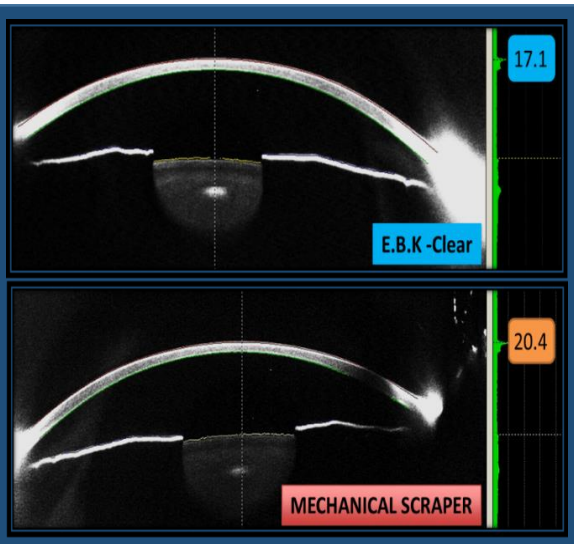

Figure 5: Post-operative Scheimflug image following EBK-Cross treatment versus mechanical scraper. EBK-Cross treated patients revealed less corneal opacity, which was shown to correlate with haze observations [19, 24].

EBK™-CROSS - A NEW TECHNIQUE FOR EPITHELIUM-OFF CORNEAL CROSSLINKING

Reduced pain and patient's discomfort

De-epithelialization is a main reason for crosslinking post-op pain [25]. A significantly lower pain intensity score was reported immediately after EBK-Cross compared to epithelium removal by mechanical scraper (2.74 ± 1.17 vs 4.54 ± 1.45; p<0.0001 respectively). Furthermore, 3 days post-operative, patients treated with EBK Cross continued to report significantly less pain compared to those treated with a mechanical scraper (0.42 ± 0.4 versus 1.08 ± 0.79; p<0.001 respectively), likely due to faster re-epithelialization (Figure 6) [19]. Kanellopolus reported less discomfort and no pain with EBK treatment as well as less erythema and light sensitivity [20].

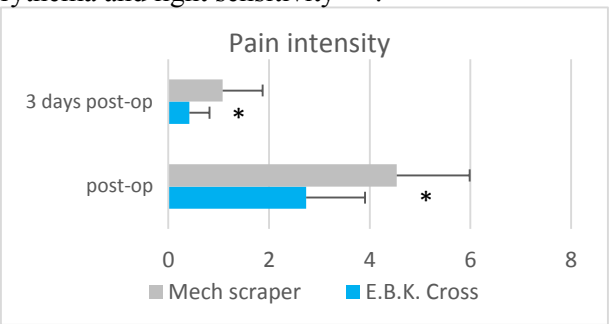

*Figure 6: Pain scores in patients undergoing EBK-Cross and epithelial removal with mechanical scraper in the immediate post-operative period and on third post-op day. The EBK-Cross treatment group showed significantly reduced pain scores compared to mechanical scraper treated subjects. * p<0.001 [19].*

Minimal procedure time

The time required for epithelium removal during Crosslinking procedure is a an important factor as prolonged exposure of the stroma to air can cause stromal dehydration and thinning which may result in harmful effects on surgical outcomes. The removal of the epithelium by mechanical scraper (w/wo alcohol pre-treatment) requires an additional debris removal step. In the EBK-Cross procedure, epithelial cells get collected in the groove as they are debrided, significantly reducing procedure time.

The time required for epithelium removal using EBK-Cross was reported as 30-60 sec by Frucht *et al.* [18]. In another study, it was shown that, using EBK-Cross significantly reduced the time of epithelium removal and debris cleaning to 18.43 ± 4.11 sec / eye from 26.26±6.33 sec / eye when using a mechanical scraper (p < 0.0001) [19].

Less adverse effects

In all clinical trials performed with EBK-Cross, no adverse effects associated with the procedure were reported. In addition, EBK-Cross is commercially being used by leading doctors in Europe and Asia and up to date there are no reports of adverse events associated with the procedure.

Trends and research outlook

Future clinical trials will investigate additional positive effects of EBK-Cross on parameters such as re-epithelialization time, pain, haze, and post-op dry eye syndrome. Furthermore, the investigation of biochemical parameters analyzing gene expression and proteomics will deliver vital information on inflammatory processes as well as on the crosslink process itself. A multi-center trial using EBK-Cross is currently ongoing in various centers in Europe and Asia.

Summary and Conclusions

EBK-Cross is an optimized technique to remove the upper epithelium minimalizing trauma to the cornea. Using this technique, re-epithelialization time is faster, less corneal haze develops and the Bowman's layer remains intact. The resulting clean and even corneal surface after epithelium removal by EBK-Cross may positively support clinical outcomes of the crosslink reaction. Patients treated with EBK-Cross prior to the crosslink procedure reported less pain and discomfort.

Orca Surgical, a part of CTZ group, was founded in 2011. Orca develops pioneering solutions for ophthalmologic surgery focused on the cornea based on its novel EBK™ (Epi-Bowman's Keratectomy) technology.

Contact Authors:
Yariv Bar-On - yariv@orcasurgical.com
Sari Prutchi-Sagiv PhD – sari@ctz.co.il
Rachel Hersh - rachel@orcasurgical.com

EBK™-CROSS - A NEW TECHNIQUE FOR EPITHELIUM-OFF CORNEAL CROSSLINKING

References

1. Dhawan S, Rao K, Natrajan S: **Complications of corneal collagen cross-linking.** *J Ophthalmol* 2011, **2011:**869015.
2. O'Brart DP: **Corneal collagen cross-linking: a review.** *J Optom* 2014, **7:**113-124.
3. Zhang X, Tao XC, Zhang J, Li ZW, Xu YY, Wang YM, Zhang CX, Mu GY: **A review of collagen cross-linking in cornea and sclera.** *J Ophthalmol* 2015, **2015:**289467.
4. Wollensak G, Spoerl E, T Seiler:**Riboflavin/ ultraviolet-a-induced collagen crosslinking for the treatment of keratoconus.** *Am J Ophthalmol* 2003, 135:620-627.
5. Kanellopoulos AJ, Krueger RR, Asimellis G: **Cross-linking and corneal imaging advances.** *Biomed Res Int* 2015, **2015:**306439
6. Raiskup F, Theuring A, Pillunat LE, Spoerl E: **Corneal collagen crosslinking with riboflavin and ultraviolet-A light in progressive keratoconus: ten-year results.** *J Cataract Refract Surg* 2015, **41:**41-46.
7. Raiskup F, Spoerl E: **Corneal crosslinking with riboflavin and ultraviolet A. Part II. Clinical indications and results.** *Ocul Surf* 2013, **11:**93-108.
8. Kanellopoulos AJ, Asimellis G: **Hyperopic correction: clinical validation with epithelium-on and epithelium-off protocols, using variable fluence and topographically customized collagen corneal crosslinking.** *Clin Ophthalmol* 2014, **8:**2425-2433.
9. Shalchi Z, Wang X, Nanavaty MA: **Safety and efficacy of epithelium removal and transepithelial corneal collagen crosslinking for keratoconus.** *Eye (Lond)* 2015, **29:**15-29.
10. Spoerl E, Mrochen M, Sliney D, Trokel S, Seiler T: **Safety of UVA-riboflavin cross-linking of the cornea.** *Cornea* 2007, **26:**385-389.
11. Tao X, Yu H, Zhang Y, Li Z, Jhanji V, Ni S, Wang Y, Mu G: **Role of corneal epithelium in riboflavin/ ultraviolet-A mediated corneal cross-linking treatment in rabbit eyes.** *Biomed Res Int* 2013, 2013:624563.
12. Bottos KM, Schor P, Dreyfuss JL, Nader HB, Chamon W: **Effect of corneal epithelium on ultraviolet-A and riboflavin absorption.** *Arq Bras Oftalmol* 2011, 74:348-351.
13. Steinberg J, Katz T, Mousli A, Frings A, Casagrande MK, Druchkiv V, Richard G, Linke SJ: **Corneal biomechanical changes after crosslinking for progressive keratoconus with the corneal visualization scheimpflug technology.** *J Ophthalmol* 2014, 2014:579190
14. Barbara R. AL, Barua A., Garzozi H., Barbara A.: **Collagen Corneal Cross-linking and the Epithelium**. *International Journal of Keratoconus and Ectatic Corneal Diseases* 2012, 1:179-184.
15. D.P.S. OB: **Corneal collagen cross-linking: A review**. *Journal of Optometry* 2014, 7:113---124.
16. B S: **Nerve structures in human central corneal epithelium**. *Graefes Arch Clin Exp Ophthalmol* 1982 1982, ;218:14-20.
17. Muller LJ VG, Pels L,: **Architecture of human corneal nerves.** *Invest Ophthalmol Vis Sci* 1997, 38:985-994
18. Frucht J.P. WD: **Epi-Bowman's keratectomy for crosslinking for keratoconus.** ESCRS 2013, poster presentation, Amsterdam 2013
19. Shetty R, Nagaraja H, Pahuja NK, Jayaram T, Vohra V, Jayadev C: **Safety and Efficacy of Epi-Bowman Keratectomy in Photorefractive Keratectomy and Corneal Collagen Cross-Linking: A Pilot Study.** *Curr Eye Res* 2015:1-7.
20. Kanellopoulos AJ: **Pilot Study - EBK™ Surface Ablation Procedure for corneal cross linking procedure according to the Athens Protocol.** *EutoTimes,* 2016
21. Shetty R: **Epi-Bowman Keratectomy ESCRS 2013, poster presentation,** Amsterdam 2013.
22. Van Dijk K, Parker J, Tong CM, Ham L, Lie JT, Groeneveld-van Beek EA, Melles GR: **Midstromal isolated Bowman layer graft for ,reduction of advanced keratoconus: a technique to postpone penetrating or deep anterior lamellar keratoplasty.** *JAMA Ophthalmol* 2014, 132:495-501
23. Wilson SL, El Haj AJ, Yang Y: **Control of scar tissue formation in the cornea: strategies in clinical and corneal tissue engineering**. *J Funct Biomater* 2012, 3:642-687.
24. Greenstein SA, Fry KL, Bhatt J, Hersh PS: **Natural history of corneal haze after collagen crosslinking for keratoconus and corneal ectasia: Scheimpflug and biomicroscopic analysis.** *J Cataract Refract Surg* 2010, 36:2105-2114.
25. Kanitkar KD, Camp J, Humble H, Shen DJ, Wang MX: **Pain after epithelial removal by ethanol-assisted mechanical versus transepithelial excimer laser debridement.** *J Refract Surg* 2000, 16:519-522


Thank
you